

# GRANULOSA HÜCRELİ TÜMÖR OLGUSUNUN LAPAROSKOPIK EVRELEMESİ

## Restaging For Laparoscopic Management Of Granulosa Cell Tumor

Hakan Nazik<sup>1</sup>, Murat Apil<sup>1</sup>, Serkan Ahmet Kale<sup>2</sup>, Meltem Aksu<sup>3</sup>

### ÖZET

Bu vaka sunumunda granulosa hücreli tümör (GHT) tanısı olan 48 yaşındaki bir kadının laparoskopik cerrahi evrelemesi sunuldu. Granulosa hücreli tümörler tüm over tümörlerinin yaklaşık %2'sini oluşturur. Hasta tanısız amaçlı 15 gün önce pelvik kitle nedeniyle opere edilmişti. Laparoskopik cerrahi evreleme yapıldı ve adjuvan kemoterapi verilmeden 8 ay geçmesine rağmen hastada herhangi bir komplikasyon gelişmedi.

**Anahtar kelime:** *Granulosa hücreli tümör; Laparoskopik evreleme*

### ABSTRACT

In the present case laparoscopic staging operation of 48 year-old woman with a diagnosis of granulosa cell tumor is presented. Granulosa cell tumors (GCTs) account for approximately 2% of all ovarian tumors. The patient had been operated with the pre-diagnosis of pelvic mass 15 days ago. Laparoscopic staging was applied and without any adjuvant therapy, the patient was under a follow-up period of 8 months without any complication.

**Key words:** *Granulosa cell tumor; Laparoscopic staging*

<sup>1</sup>Department of Obstetrics and Gynecology, Adana Numune Education and Research Hospital

<sup>2</sup>Department of Obstetrics and Gynecology, Kocaeli Derince Education and Research Hospital.

<sup>3</sup>Department of Obstetrics and Gynecology, BSK Metropark Hospital

Hakan Nazik, M.D.  
Murat Apil, M.D.  
Serkan Ahmet Kale, M.D.  
Meltem Aksu, M.D.

**Corresponding Author:**

Hakan Nazik, M.D.  
Department of Obstetrics and Gynecology,  
Adana Numune Education and Research Hospital  
01330 Adana TURKEY

**Phone:**

+90 542 686 11 20

**e-mail:**

drhakannazik@gmail.com

## INTRODUCTION

Granulosa-theca cell tumors, more commonly known as granulosa cell tumors (GCTs), belong to the sex cord–stromal category and include tumors composed of granulosa cells, theca cells, and fibroblasts in varying degrees and combinations. GCTs account for approximately 2% of all ovarian tumors and can be divided into adult (95%) and juvenile (5%) types based on histologic findings (1).

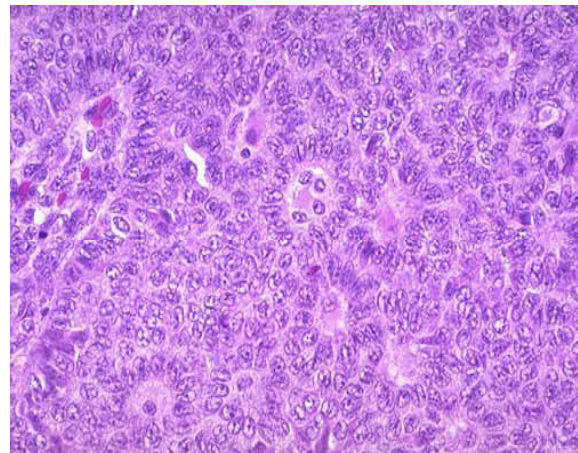
Both subtypes commonly produce estrogen, and estrogen production often is the reason for early diagnosis. However, while adult GCTs (AGCTs) usually occur in postmenopausal women and have late recurrences, most juvenile GCTs (JGCTs) develop in individuals younger than 30 years and often recur within the first 3 years (2).

Recognition of the signs and symptoms of abnormal hormone production and consideration of these tumors in the differential diagnosis of an adnexal mass can allow for early identification, timely surgical management, and excellent cure rates. Despite the good overall prognosis, long-term follow-up always is required in patients with GCTs. Reports of extraovarian GCTs can be found in the literature and may lend support to the derivation of this class of tumors from epithelium of the coelom and mesonephric duct (3). In the present case laparoscopic staging operation of the patient with a diagnosis of granulosa cell tumor is presented.

## CASE

A 48 year-old woman was referred to our department with a diagnosis of granulosa cell tumor of the right ovary. She had been operated with the prediagnosis of pelvic mass 15 days ago (Figure 1). Sonographic evaluation revealed normal pelvic anatomy except operated right ovary. She has been scheduled for a staging operation. Preoperative CA125 level was 14,6 mIU/mL. There was no abrupt onset or rapid prog-

ression of endocrinologic manifestations to heighten the suspicion of a neoplastic process and there was no abnormal uterin bleeding history. Other ancillary laboratory studies that may be useful in differential diagnosis included stool guaiac testing, complete blood count (CBC), blood chemistries, urinalysis and all were in normal ranges. Laparoscopic approach was applied and partial omentectomy, total laparoscopic hysterectomy with contralateral oophorectomy, pelvic and para-aortic lymph node sampling were successfully accomplished. The patient was discharged from the hospital on the second postoperative day. One paraaortic and eight pelvic lymph nodes were sampled and the pathologic examination of these nodes revealed no metastasis. The pathologic examination of all the specimen were tumor negative. The patient was considered to be stage 1A. Several other tumor markers have been evaluated in patient with GCTs. Inhibin B and estrogen have been studied afterwards in this woman and was found to be in normal ranges. The patient was under the follow-up period without any adjuvant therapy and 8 months passed without any complication when this report was prepared.



**Figure 1:** The histological appearance of granulosa cell tumor

## CONCLUSION

GCTs are thought to be tumors of low malignant potential. Most of these tumors follow a benign course, with only a small percentage showing aggressive behavior. Metastatic disease can involve any organ system, although tumor growth usually is confined to the abdomen and pelvis (4).

Approximately 25,000 new cases of ovarian cancer are diagnosed in the United States each year. The disease accounts for more than 14,000 deaths in the United States annually and is the leading cause of death from gynecologic malignancies. Because sex cord–stromal tumors account for only 5% of all ovarian tumors and approximately 8% of all malignant ovarian neoplasms, each year only 1500-2000 new cases of these tumors are diagnosed in the United States. Unlike epithelial ovarian cancers, no racial or ethnic predilection is found for ovarian germ cell or sex cord–stromal tumors. The incidence of this group of tumors essentially is the same throughout the world, as witnessed by similar frequency of these tumors in Japan, Sweden, and the Caribbean (5).

AGCTs and JGCTs have very good cure rates due to the early stage of disease at diagnosis. More than 90% of AGCTs and JGCTs are diagnosed before spread occurs outside the ovary. Five-year survival rates usually are 90-95% for stage I tumors compared to 25-50% for patients presenting with advanced-stage disease. Although 5-year survival rates are quite good, AGCTs have a propensity for late recurrence, some occurring as many as 37 years after diagnosis. Mean survival after the diagnosis of a recurrence is 5 years (6).

Approximately 20% of patients diagnosed with GCTs die of their disease over the course of their lifetime. Morbidity related to GCTs primarily is due to endocrine manifestations of the disease. Physical changes brought on by high estrogen levels from the tumor usually regress upon removal of the tumor. However, a small group of patients present with symptoms of

androgen excess from the tumor. Changes caused by androgen excess may be permanent or may only partially regress over time. Serious estrogen effects can occur in various end organs. Unopposed estrogen production by these tumors has been shown to cause stimulation of the endometrium. Anywhere from 30-50% of patients develop endometrial hyperplasia and another 8-33% have endometrial adenocarcinoma. Patients also may be at an increased risk for breast cancer, although a direct correlation has been difficult to prove (7).

Granulosa cell tumors can occur in the juvenile and adult male testes, albeit very rarely. The frequency of GCTs in the male testes is even lower than that of GCTs in females and is the least common sex cord stromal tumor in the testes (8). AGCTs account for 95% of all GCTs and usually are seen in postmenopausal women, with a median age at diagnosis of 52 years. JGCTs comprise only 5% of all GCTs, and almost all of these tumors are found in patients younger than 30 years. Theca cell tumors (ie, thecomas) account for less than 1% of all ovarian tumors, and the mean age at diagnosis is 53 years. These tumors are rare in women younger than 30 years, with the exception of the luteinized thecoma, which tends to occur in younger women (9).

GCTs are the most common estrogen-producing neoplasms in females and are found to produce estradiol in approximately 40-60% of patients. This estradiol production is dependent on stimulation by testosterone secreted by the theca cells. However, not all GCTs are hormonally active or have theca cells that secrete testosterone, and this type of testing lacks sensitivity and specificity. In a case with Stage Ia granulosa cell tumor, laparoscopic staging can be a useful approach.

## REFERENCES

1. Quirk JT, Natarajan N. Ovarian cancer incidence in the United States, 1992-1999. *Gynecol Oncol* 2005; 97(6):519.
2. Evans AT 3rd, Gaffey TA, Malkasian GD Jr, Annegers JF. Clinicopathologic review of 118 granulosa and 82 theca cell tumors. *Obstet Gynecol* 1980; 55(3):231.
3. Gershenson DM. Management of ovarian germ cell tumors. *J Clin Oncol* 2007;25(20):2938-43.
4. Young R, Clement PB, Scully RE. The ovary. In: *Surgical Pathology*, Sternberg SS (Ed), Raven Press, New York 1989;p.1687.
5. Siegel R, Ward E, Brawley O, Jemal A. Cancer statistics, 2011: The impact of eliminating socioeconomic and racial disparities on premature cancer deaths. *CA Cancer J Clin* 2011;61(4):212.
6. Gershenson DM. Management of early ovarian cancer: germ cell and sex cord-stromal tumors. *Gynecol Oncol* 1994;55(3Pt2):62-72.
7. Adamian RT. Hyperplastic processes and endometrial cancer in patients with hormone-producing ovarian tumors. *Vopr Onkol* 1991;37(1):48.
8. Küçükodacı Z, Keleş M, Yapanoğlu T, et al. Adult type granulosa cell tumor of the testis case report and review of the literature. *EAJM* 2008;40(1):39-41.
9. Boyce EA, Costaggini I, Vitonis A, et al. The epidemiology of ovarian granulosa cell tumors: a case-control study. *Gynecol Oncol* 2009;115(2):221.